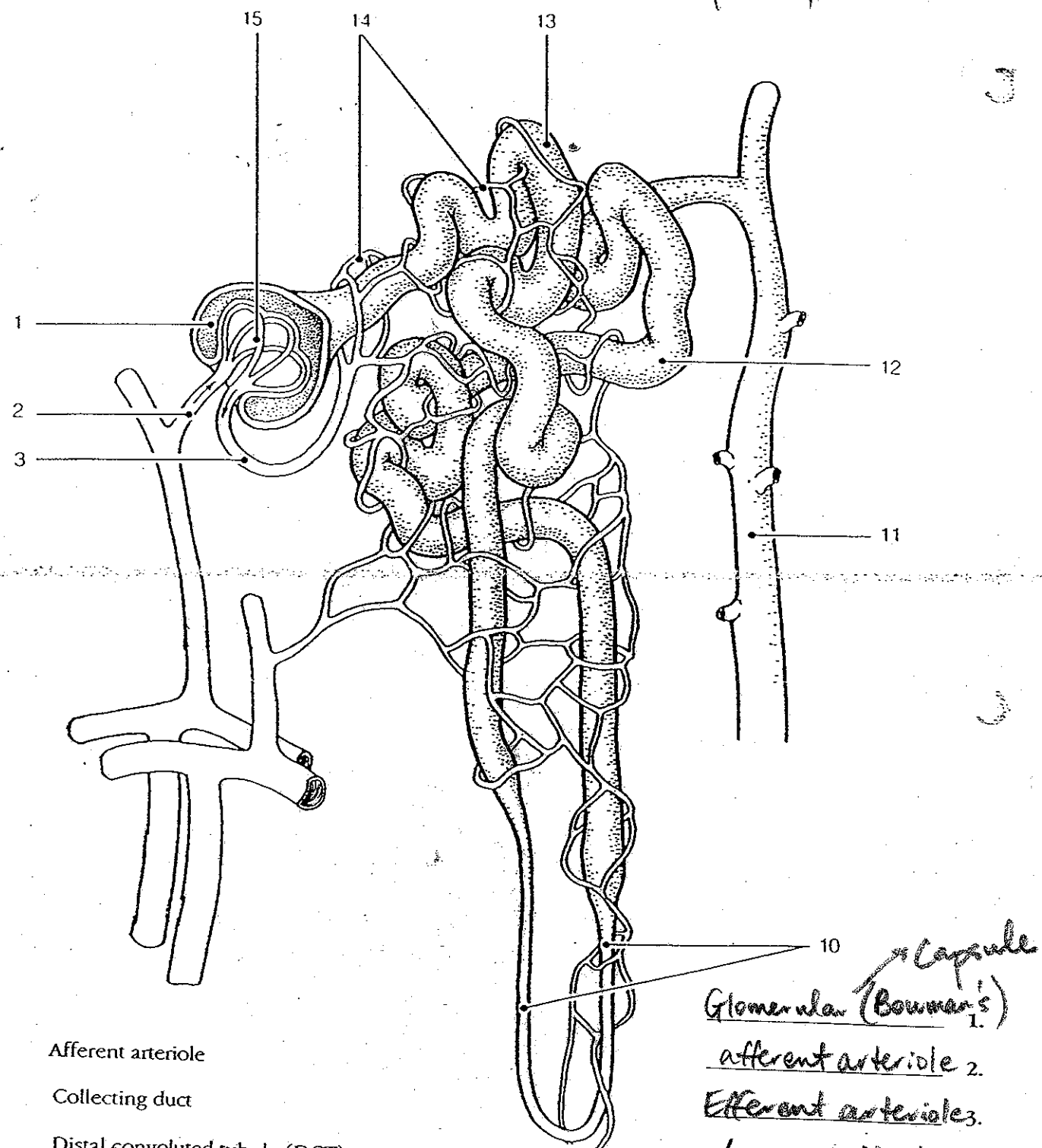


A Nephron - Micro Structure

KEY



- Afferent arteriole
- Collecting duct
- Distal convoluted tubule (DCT)
- Efferent arteriole
- Glomerular capsule
- Glomerulus
- Loop of Henle
- Proximal convoluted tubule (PCT)
- Peritubular capillaries

- Glomerular (Bowman's) Capsule 1.
- afferent arteriole 2.
- Efferent arterioles 3.
- Loop of Henle 10.
- Collecting Duct 11.
- DCT 12.
- PCT 13.
- Peritubular Capillaries 14.
- Glomerulus 15.